


PATIENT

Duffy Duhasky

PRESENTING CLINICAL SIGNS

 History: Tachycardia with a heart murmur- grade 2/6, systolic. Assess prior to dental. Poor appetite- pain, gastrointestinal disease, pancreatitis, systemic disease, food refusal.
 BP: 140mmHg. Current Medications: Solensia 1ml q 30 days.

SPECIES

Feline

ECHOCARDIOGRAM FINDINGS

2D, m-mode, color flow and doppler imaging is available. The left ventricular wall is normal in dimension. There is a mildly hyperechoic endocardium consistent with fibrosis. The papillary muscles are mildly remodeled and hyperechoic. The endocardium also appears remodeled. The left atrium is normal in size. The right atrium is normal in size. The right ventricle appears normal. The mitral valve is normal in structure and mobility. Blood flow through both the LVOT and RVOT is normal in velocity. No pleural or pericardial effusion seen. No obvious cardiac tumors.

BREED

Scottish Fold

SEX

Male Neutered

CARDIAC CHART
AGE

7 years

WEIGHT

9.3lbs

INTERPRETED BY

 Maggie Machen Lamy,
 DVM DACVIM
 (Cardiology)

IMAGING PERFORMED BY

Kelly Reschny, RVT

HOSPITAL NAME

 Bronte Road Animal
 Hospital

REFERRING VET

Dr. McGrath

INVOICE

28398

DATE

1/17/23

FELINE CARDIAC PARAMETERS	BODY WEIGHT (kg)	HR (BPM)	IVSd (cm) <small>(Moise, Pipers)</small>	LVIDd (cm) <small>(Moise, Pipers)</small>	LVWd (cm) <small>(Moise, Pipers)</small>	FS (%)	EF (%)
NORMAL PARAMETER	-----	150-240	0.35-0.55	<2 <small>(mean 1.5)</small>	3.5-0.55	35-67	80-100
PATIENT	4.2	188	0.43	1.5	0.47	53	87
FELINE CARDIAC PARAMETERS	LA/AO <small>(Boon)</small>	LA/AO HEART BASE <small>(Swe) (Abbott)</small>	LA 2D short axis Base view <small>(cm) (Abbott)</small>	LVOT VEL <small>(m/s)</small>	RVOT VEL <small>(m/s)</small>	E max <small>(m/s)</small>	
NORMAL	<1.5	<1.3	<1.2		<1.6	<1.3	<0.9
PATIENT	1.1	1.1	1.0		0.82	0.70	NM
<i>*Note: All measurements based upon multi-modal images and methods. An average value is reported.</i> Adapted from June Boon, Veterinary Echocardiography, 1998 Abbott J & MacLean H JVIM 2006;20: 111-119, Moise et al. Am J Vet Res 47:1476, 1986. Pipers et al. Am J Vet Res 40:882, 1979.							

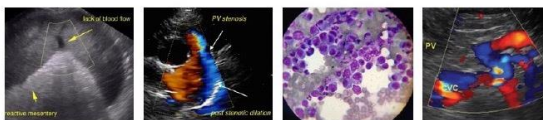
INTERPRETATION OF THE FINDINGS & FURTHER RECOMMENDATIONS

Overtly normal cardiac structure and function. The LV wall thickness is normal and there is no evidence of elevated left atrial pressure. There is mild remodeling and fibrosis of the left ventricular wall, which is likely a normal variant. Serial echocardiography will be necessary to determine progression. Additionally, no cause for the murmur is identified in this study, making it likely physiologic in origin (i.e., secondary to tachycardia, volume changes, etc.).

Given these findings, no medications are indicated.

No cardiac contraindication for general anesthesia. Mild IV fluid restriction is advised. Risk for complication with steroid use typically follows LA dilation, which in this case is low. That being said, any cat can experience unexpected signs of intolerance and monitoring of RR/RE is advised particularly in the initiation phase.

Recommend recheck echocardiogram in 1 year to reassess murmur origin, and screen for



PATIENT

Duffy Duhasky

development of disease the pre-existing murmur may mask.

SPECIES

Feline

BREED

Scottish Fold

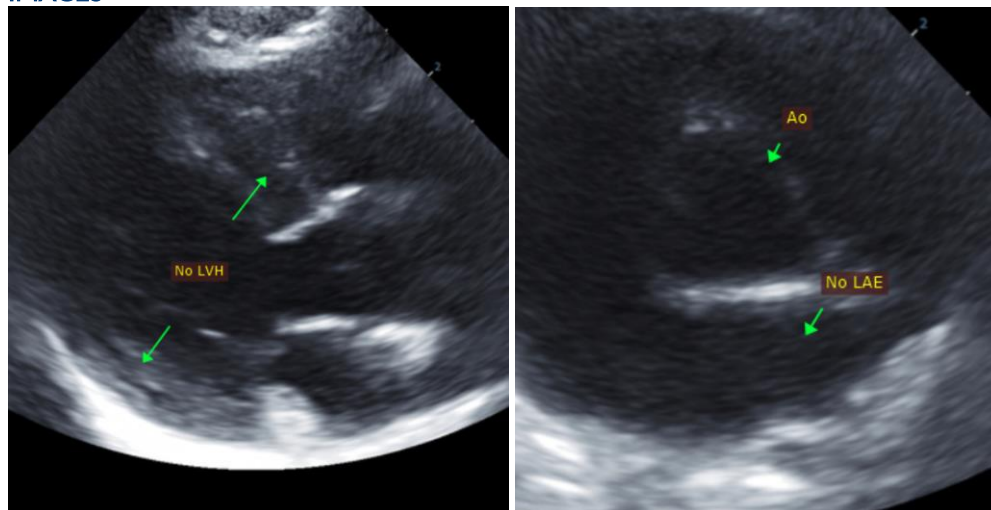
SEX

Male Neutered

AGE

7 years

IMAGES



WEIGHT

9.3lbs

The information and recommendations provided are based on the images presented by the referring veterinarian. No evaluation can be communicated regarding pathology that was not visible in the image/video clips provided.

INTERPRETED BY

Maggie Machen Lamy,
DVM DACVIM
(Cardiology)

Thank you for this referral. This report was generated using transcription software, and minor dictation errors may be present. If the clinical or image interpretation does not parallel your findings or if I can be of any further assistance, please contact me.

Maggie Machen Lamy, DVM
Diplomate of the American College of Veterinary Internal Medicine (Cardiology)
info@sonopath.com

IMAGING PERFORMED BY

Kelly Reschny, RVT

HOSPITAL NAME

Bronte Road Animal
Hospital

REFERRING VET

Dr. McGrath

INVOICE

28398

DATE

1/17/23